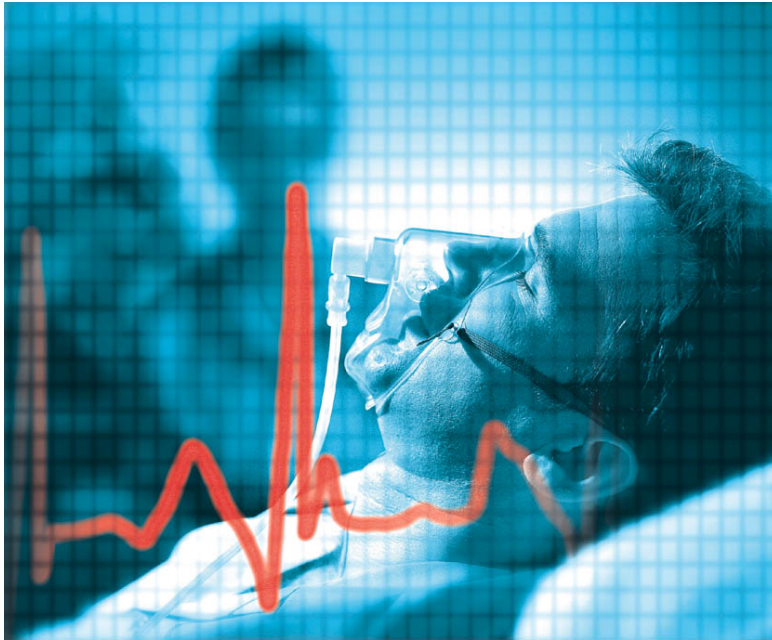

# The Six Second ECG



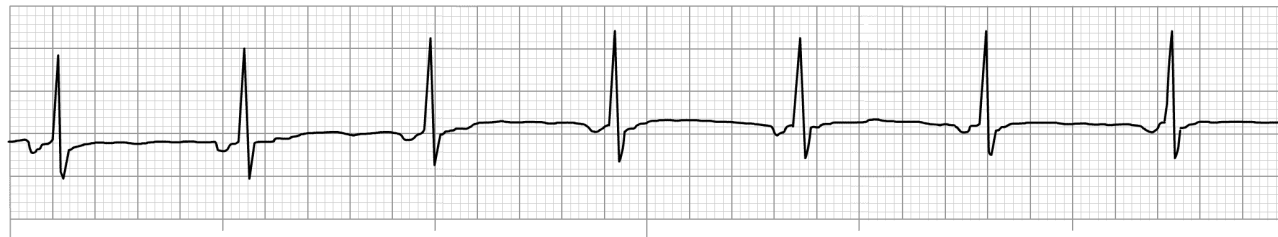
## ECG Quiz 2A

Version 2.1

## The Six Second ECG Quiz 2A (version 2.1)

Please answer the following questions by circling the correct answer on the accompanying answer sheet. **Please do not write on this test booklet.** All rhythms are six second ECGs from lead II.

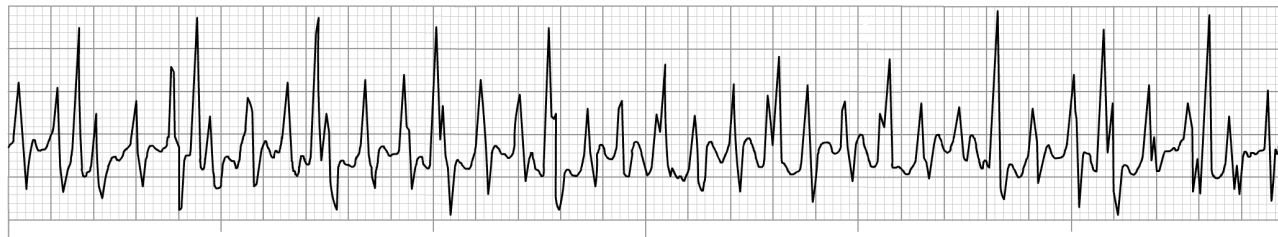### Question 1



This ECG rhythm is called:

- a) Sinus bradycardia
- b) Ectopic atrial rhythm
- c) Sinus rhythm with aberrant intraventricular conduction
- d) Accelerated junctional rhythm

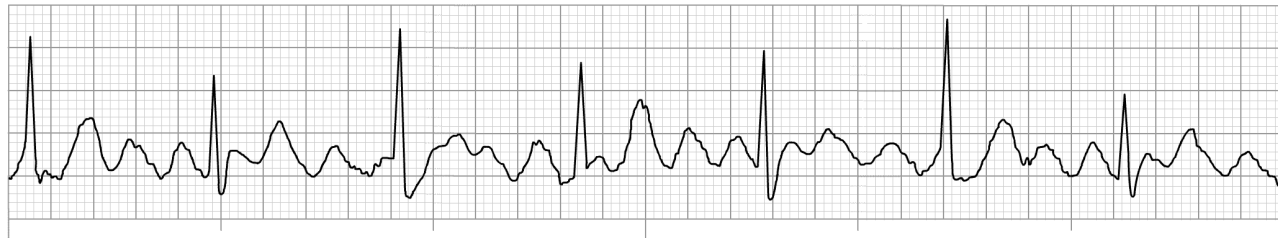
### Question 2



This ECG rhythm is called:

- a) Supraventricular tachycardia (SVT)
- b) Movement artifact
- c) Atrial fibrillation
- d) Atrial flutter

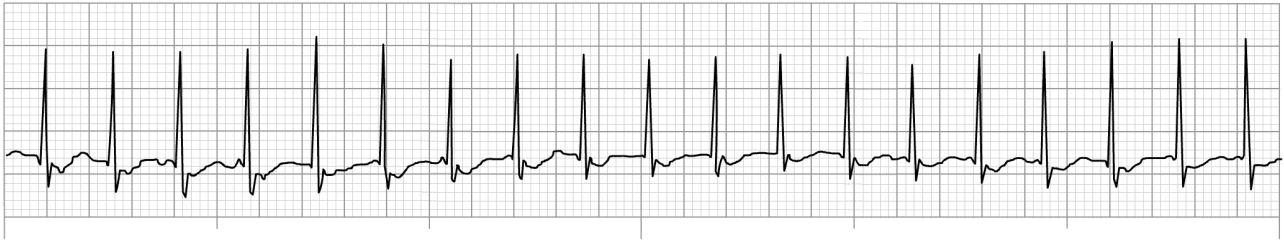### Question 3



This ECG rhythm is called:

- a) Atrial fibrillation
- b) Sinus rhythm with movement artifact
- c) Atrial flutter with 2:1 ventricular response
- d) Atrial flutter with 4:1 ventricular response

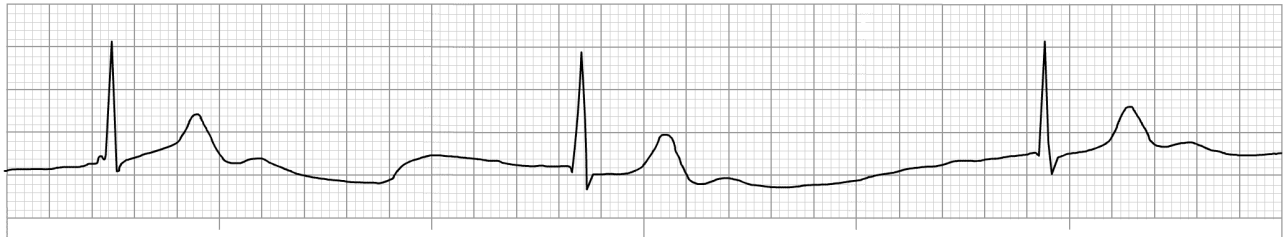### Question 4



This ECG rhythm is called:

- a) Sinus tachycardia
- b) Atrial fibrillation with rapid ventricular response
- c) Junctional tachycardia
- d) Ventricular tachycardia

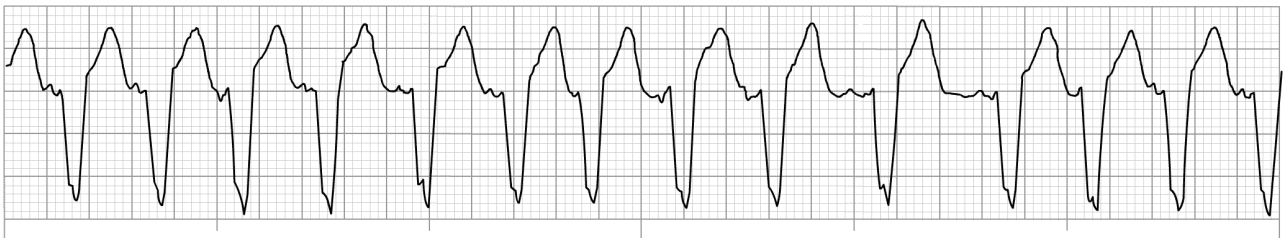
### Question 5



This ECG rhythm is called:

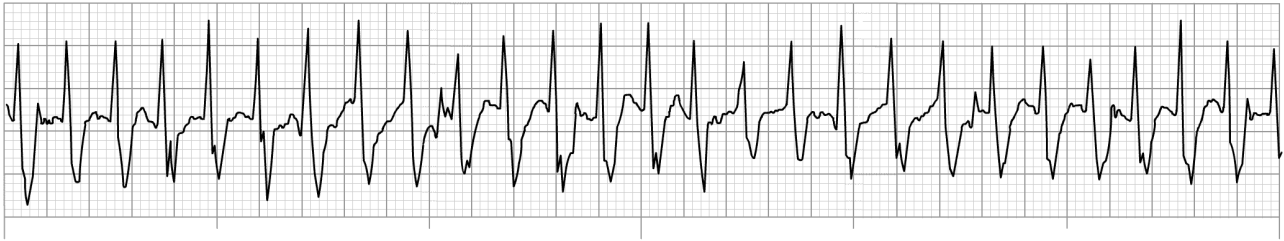- a) Sinus arrhythmia
- b) Junctional rhythm
- c) Junctional bradycardia
- d) Sinus bradycardia

### Question 6



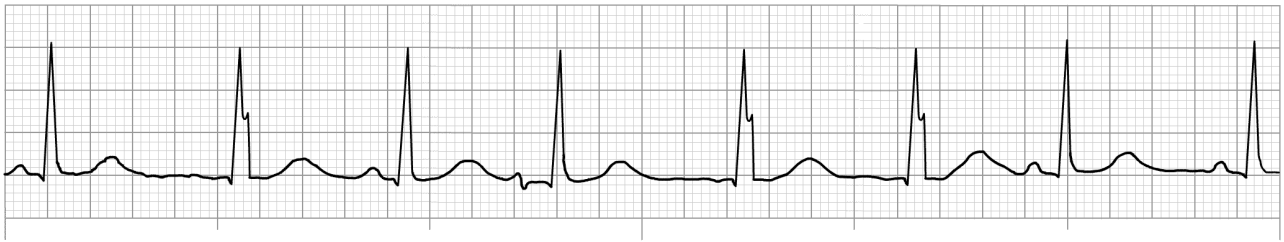This ECG rhythm is called:

- a) Multifocal atrial tachycardia
- b) Sinus tachycardia
- c) Junctional tachycardia
- d) Ventricular tachycardia

**Question 7**

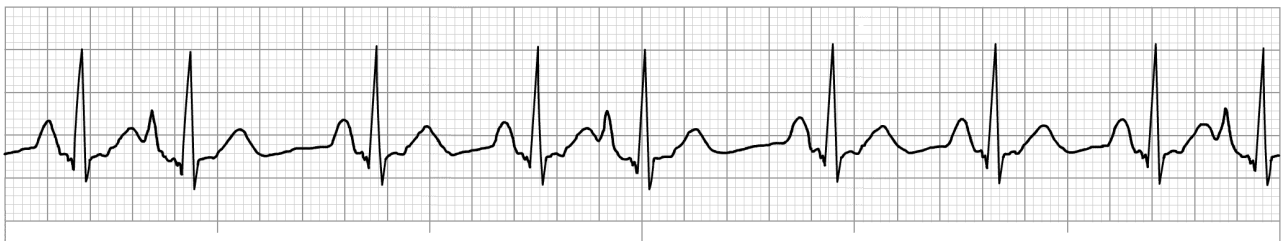This ECG rhythm is called:

- a) Junctional tachycardia
- b) Supraventricular tachycardia (SVT)
- c) Sinus tachycardia
- d) Atrial fibrillation with fast ventricular response

**Question 8**

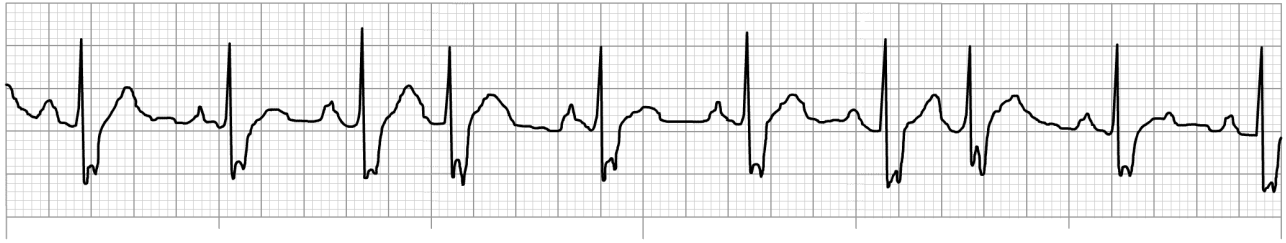
This ECG rhythm is called:

- a) Sinus arrhythmia
- b) Wandering pacemaker
- c) Sinus rhythm
- d) Atrial fibrillation

**Question 9**

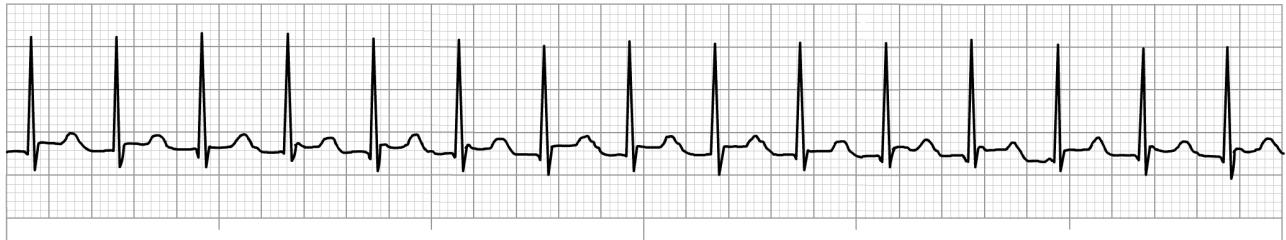This ECG rhythm is called:

- a) Sinus arrhythmia
- b) Atrial fibrillation with ectopic atrial beats
- c) Sinus tachycardia with premature ventricular complexes (PVCs)
- d) Sinus rhythm with premature atrial complexes (PACs)

**Question 10**

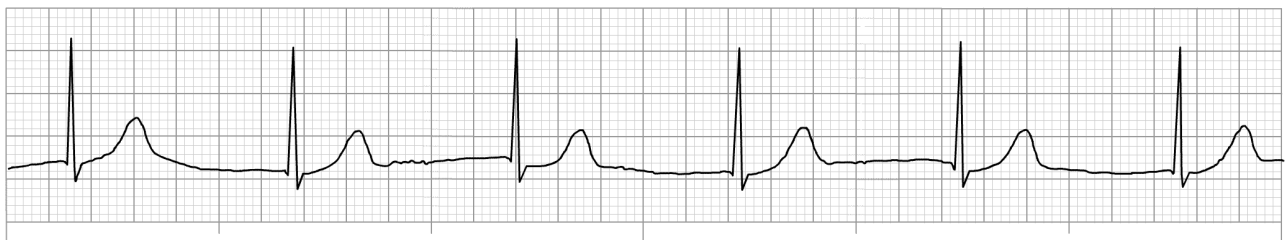This ECG rhythm is called:

- a) Sinus rhythm with aberrant intraventricular conduction and two PVCs
- b) Atrial fibrillation with aberrant intraventricular conduction
- c) Sinus rhythm with two PJs with aberrant intraventricular conduction
- d) Sinus arrhythmia with aberrant intraventricular conduction

**Question 11**

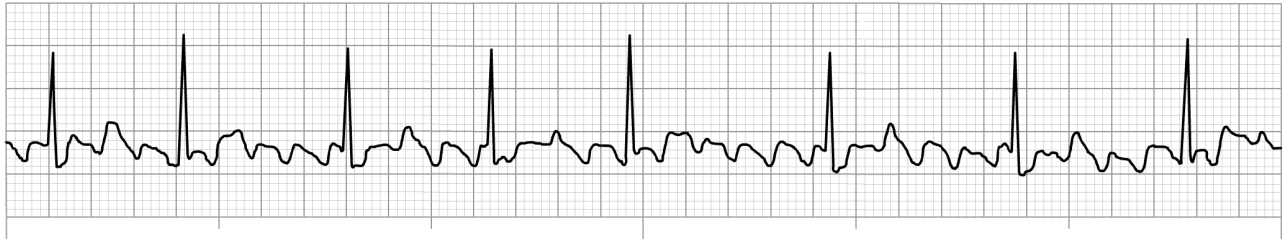This ECG rhythm is called:

- a) Atrial fibrillation with rapid ventricular response
- b) Accelerated junctional rhythm
- c) Sinus tachycardia
- d) Junctional tachycardia

**Question 12**

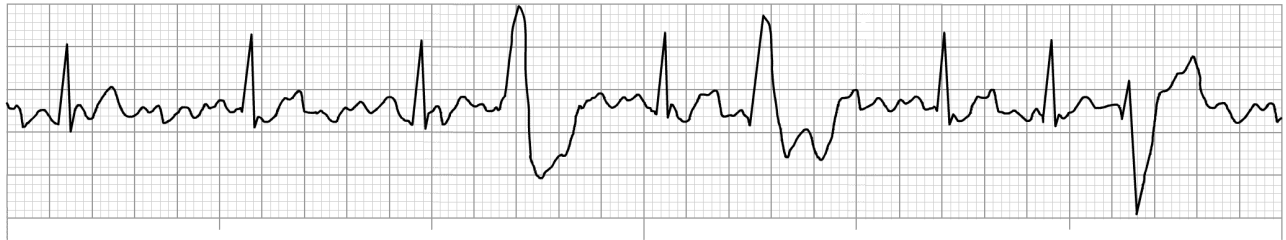
This ECG rhythm is called:

- a) Wandering pacemaker
- b) Sinus rhythm
- c) Junctional rhythm
- d) Accelerated idioventricular rhythm

**Question 13**

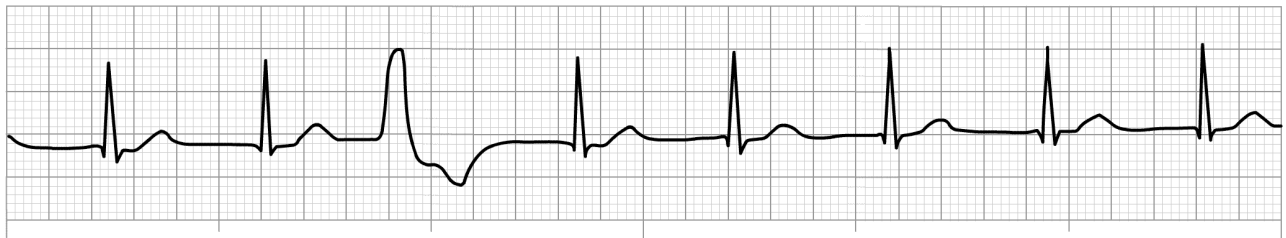This ECG rhythm is called:

- a) Atrial flutter with variable ventricular response
- b) Sinus rhythm with PACs
- c) Atrial fibrillation with fast ventricular response
- d) Sinus arrhythmia

**Question 14**

This ECG rhythm is called:

- a) Atrial flutter with multifocal PVCs
- b) Atrial fibrillation with multifocal PVCs
- c) Sinus bradycardia with multifocal PVCs
- d) Accelerated junctional rhythm with PACs

**Question 15**

This ECG rhythm is called:

- a) Sinus rhythm with a PVC
- b) Sinus rhythm with a PAC
- c) Accelerated junctional rhythm with a PVC
- d) Junctional tachycardia with a PVC